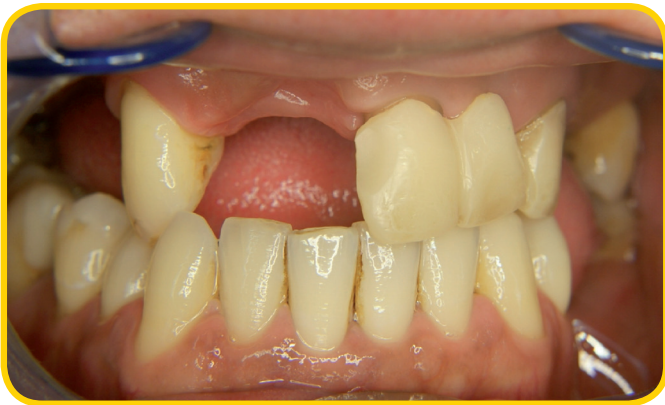

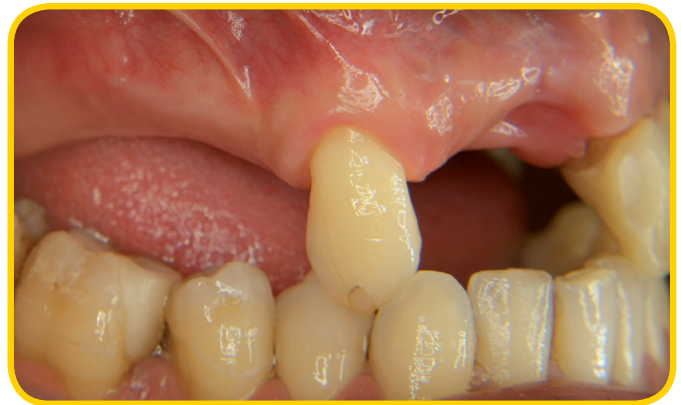# Surgical user report with eight IMPLA Cylindrical implants by Dr. Philipp Plugmann MSc MBA, Leverkusen

Patient's oral situation before proceeding:

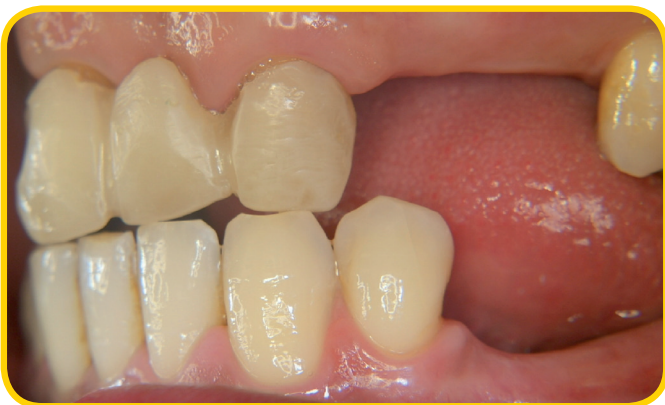Multiple gaps in the upper and lower jaw. Additionally, a terminal gap can be seen at the far end of the upper jaw (right side on the patient). Good amount of bone available in the posterior tooth area. Less bone available in the upper incisal area.



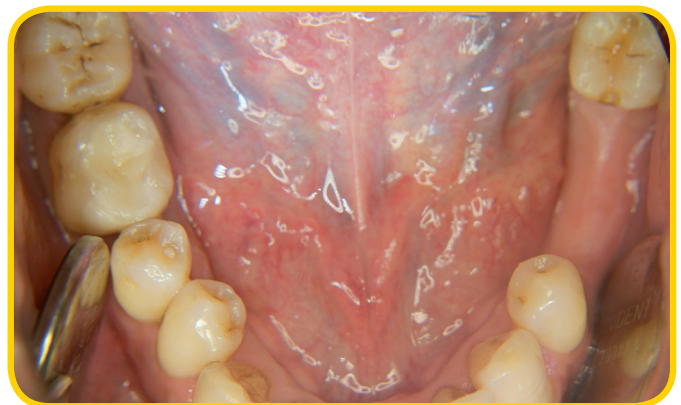Initial situation of the teeth/front view



Initial situation of the teeth/right side

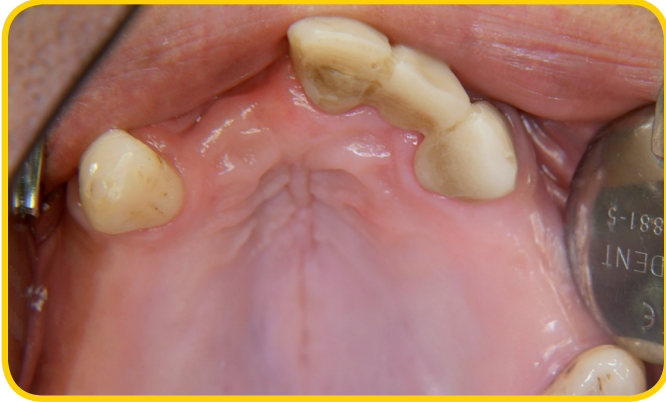

Initial situation of the teeth/left side

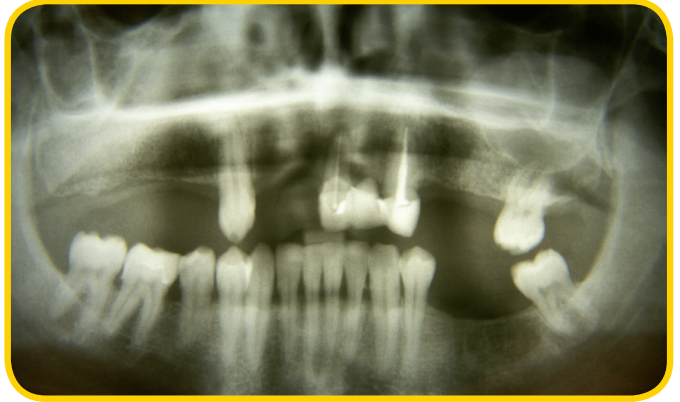


Initial situation of the lower jaw

# Surgical user report with eight IMPLA Cylindrical implants by Dr. Philipp Plugmann MSc MBA, Leverkusen

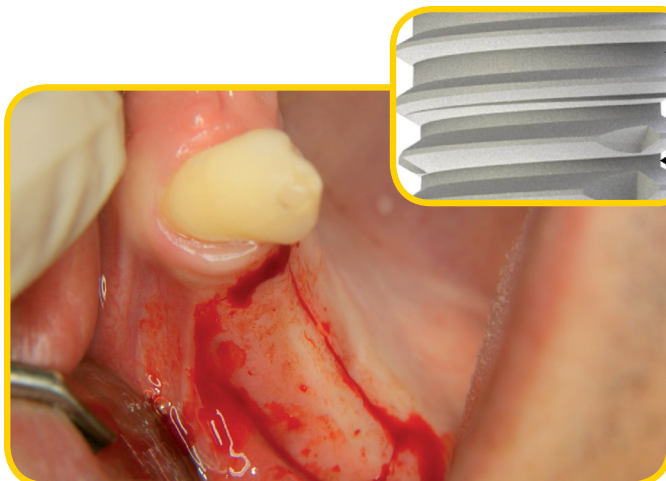


Initial situation of the upper jaw

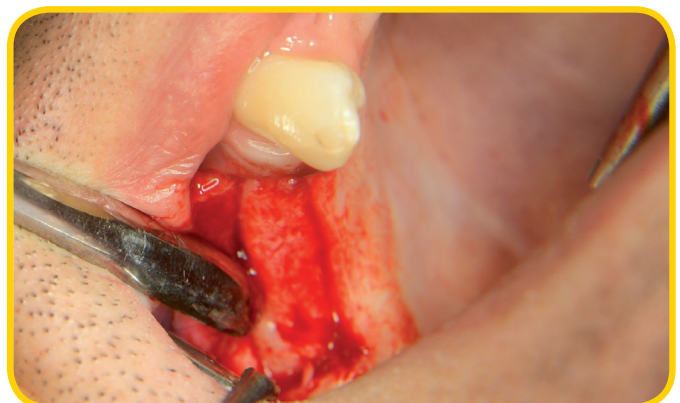

Presurgical panorama x-ray

First, I exposed the bone using a scalpel and a sharp curette. Because this case deals with a D4 bone, I decided to use a IMPLA Cylindrical implant. Thanks to the cylindrical structure and especially co-ordinated thread sides, this implant offers a high primary stability in cases such as this one.



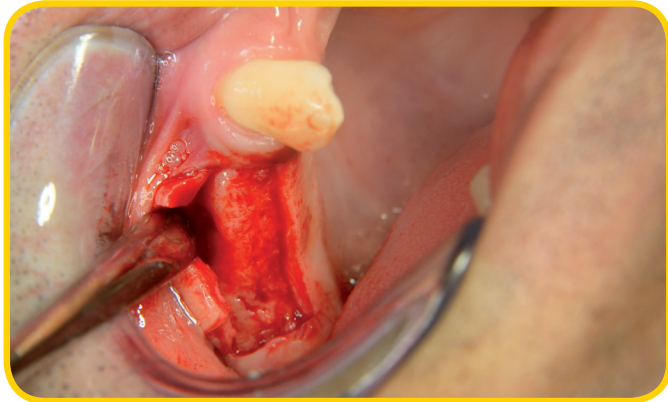
Incision in the 1st quadrant



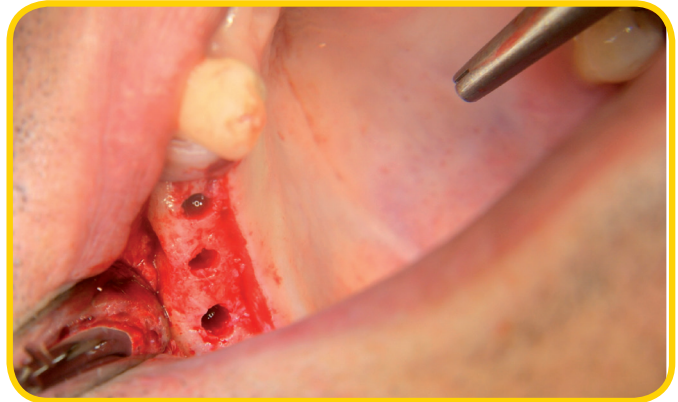
Flap exposing the surgical field,  
1st quadrant



# Surgical user report with eight IMPLA Cylindrical implants by Dr. Philipp Plugmann MSc MBA, Leverkusen

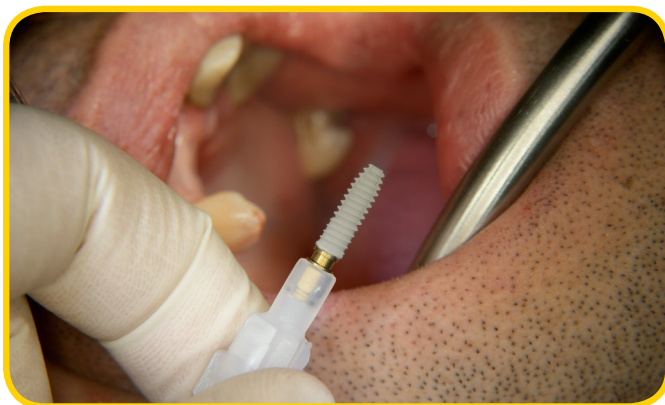

Display of the vestibular bone structure,  
1st quadrant

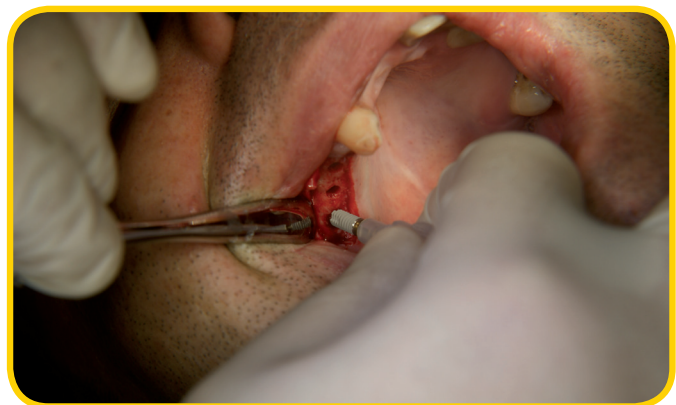


Prepared implant bed, positions 14, 15  
and 16

Thanks to the self-tapping thread of IMPLA Cylindrical implant, I only had to apply the pilot and extension drilling techniques. This meant that there was no need for extra cutting of the thread in the bone. With the help of the acrylic insertion aid and “no-touch” technology, I could insert and screw the implants quickly and easily into the drill holes.



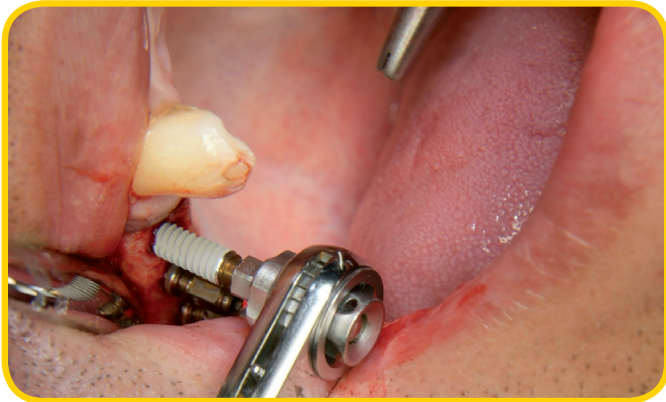
Preparation of the implant



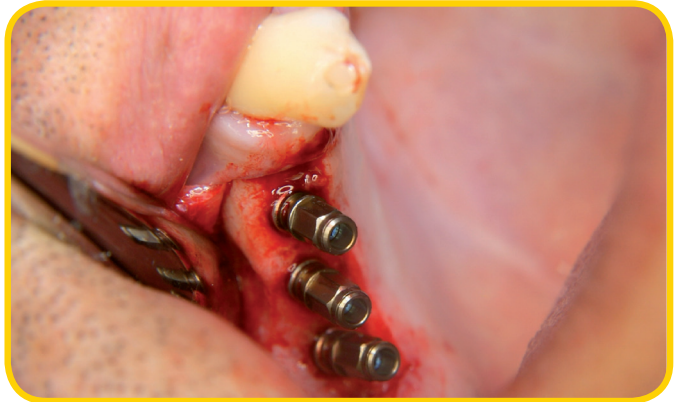
1st step, manually screwing the implant in

# Surgical user report with eight IMPLA Cylindrical implants by Dr. Philipp Plugmann MSc MBA, Leverkusen

Final stage of screwing in the implant with help of a torque wrench.

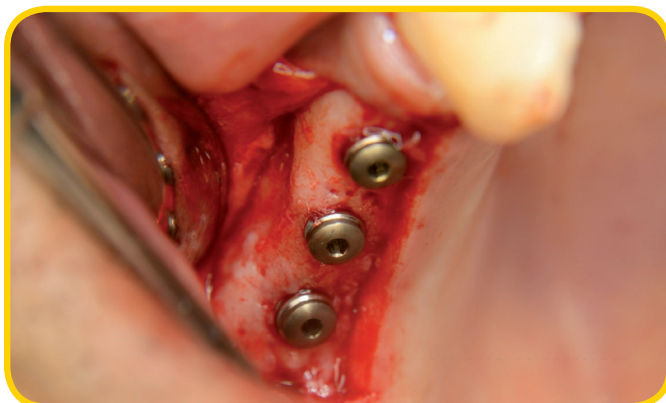

2nd step, further screwing in with a the adjustable IMPLA ratchet, 30 Ncm for primary stability.

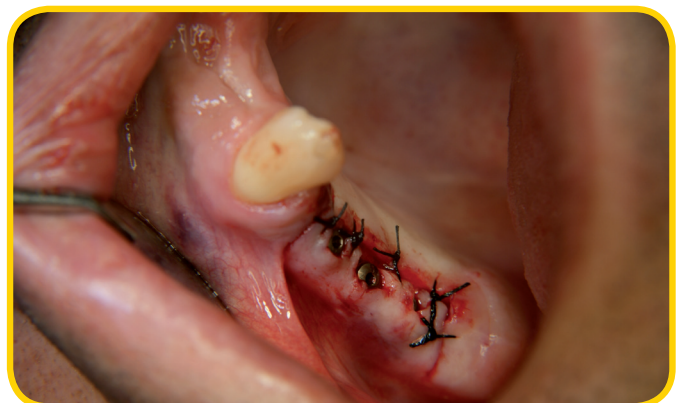

Insertion posts on top of the implants, positions 14, 15 and 16

After taking off the insertion posts and screwing on the healing caps, the mucous membrane is fitted with several 4.0 interrupted sutures (Ethicon, braided silk, non-absorbable).



Healing caps in positions 14, 15 and 16

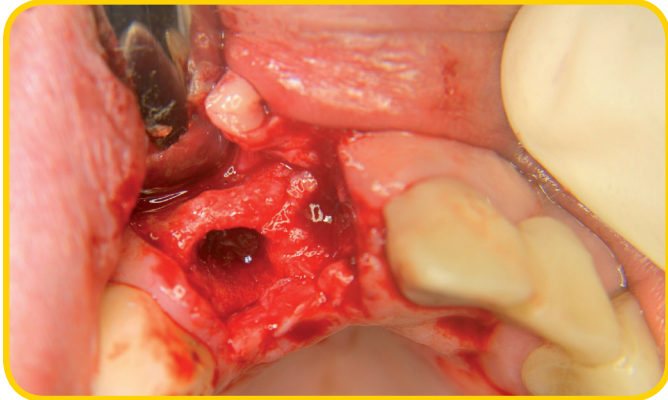


Closing up the 1st quadrant

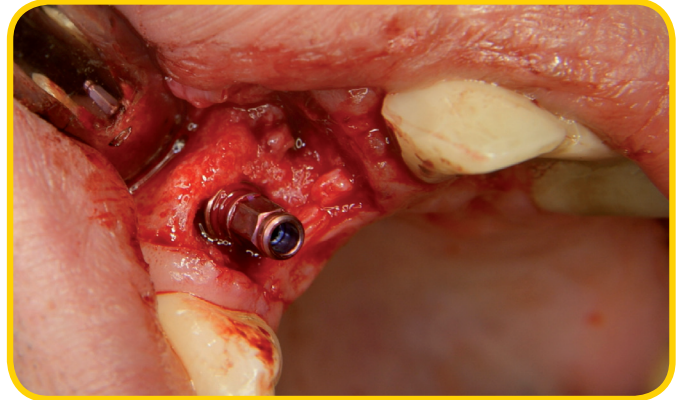


# Surgical user report with eight IMPLA Cylindrical implants by Dr. Philipp Plugmann MSc MBA, Leverkusen

While I was exposing the bone in position 12, I noticed that the available bone structure would not be sufficient.

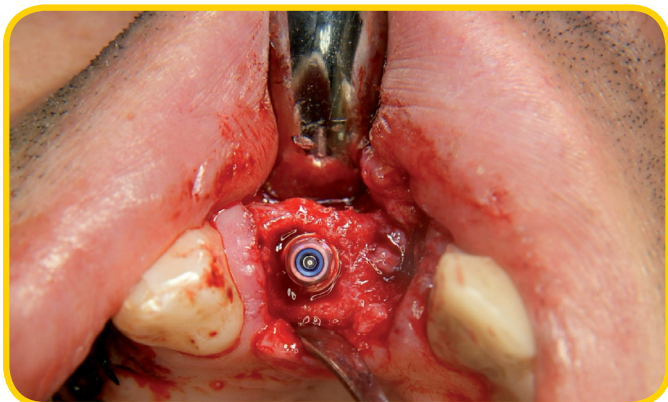


Surgically opening position 12

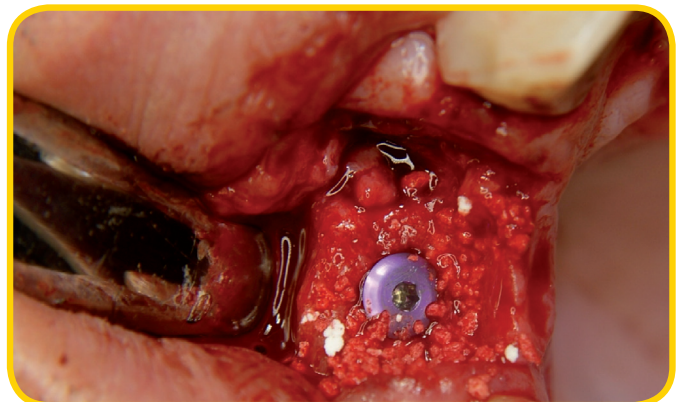


Inserted implant with insertion post,  
position 12

Here I chose an augmentative bone construction using the bone augmentation material CERASORB from the company Riemsler as well as a resorbable Epiguide membrane. After I inserted the implant and screwed on the healing cap, I remodelled the bone structure using bone augmentation material. This made sure that the neck of the implant wouldn't be seen after surgery.

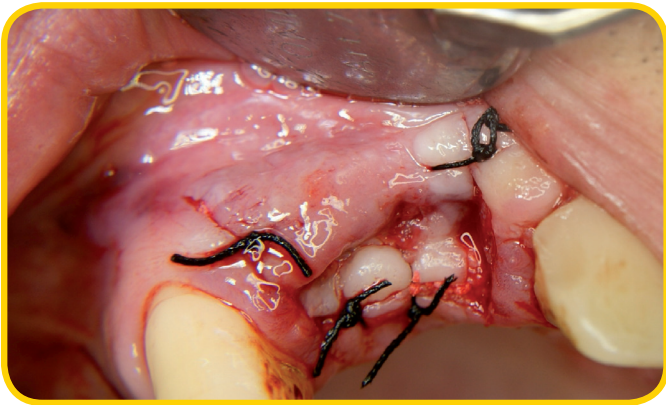


View of the bone situation

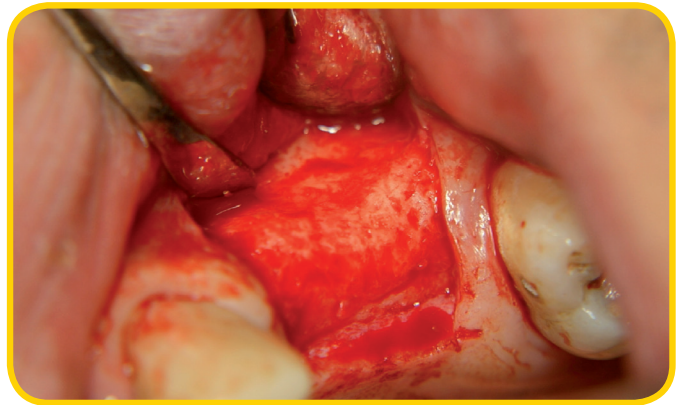


Implant with a healing screw and bone  
augmentation material

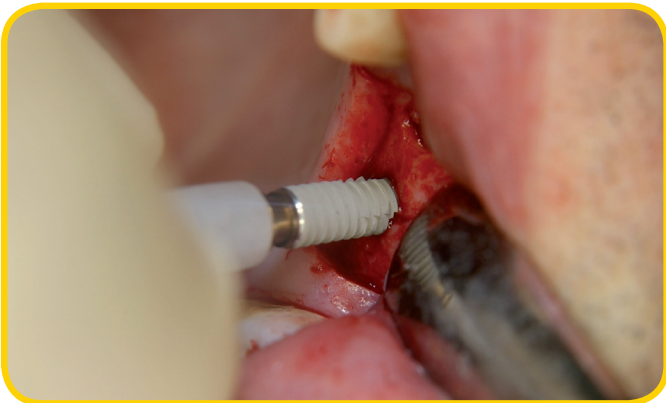
# Surgical user report with eight IMPLA Cylindrical implants by Dr. Philipp Plugmann MSc MBA, Leverkusen



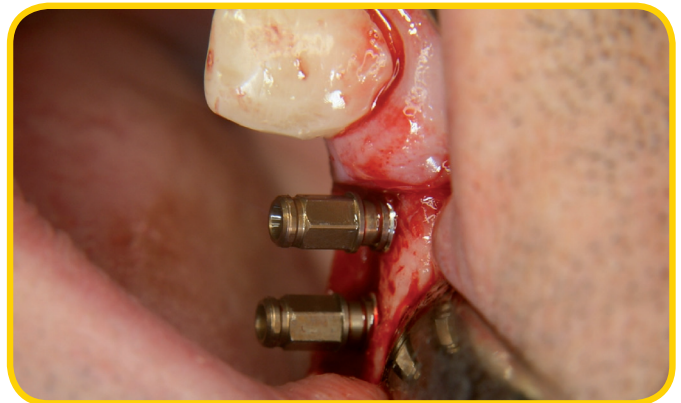
Sutures, position 12



Incision in the 2nd quadrant

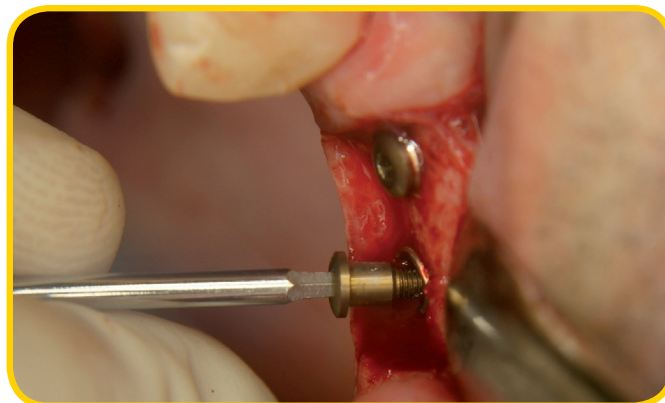


Screwing the implant into position 25



Parallel implants with insertion posts in positions 24 and 25

After inserting the implants and removing the insertion posts, the implants were sealed with the healing caps.

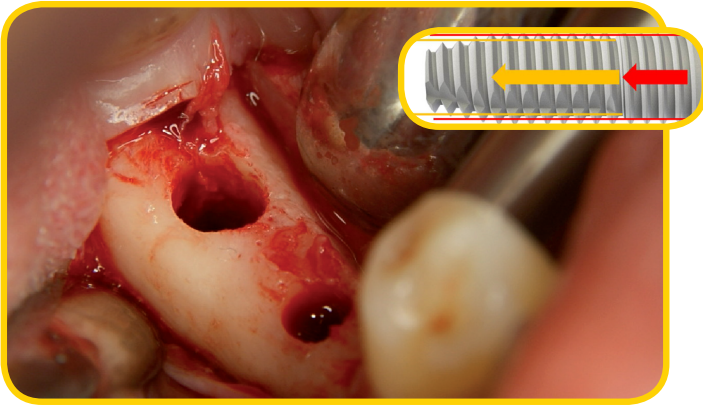


Screwing in the healing caps in positions 24 and 25

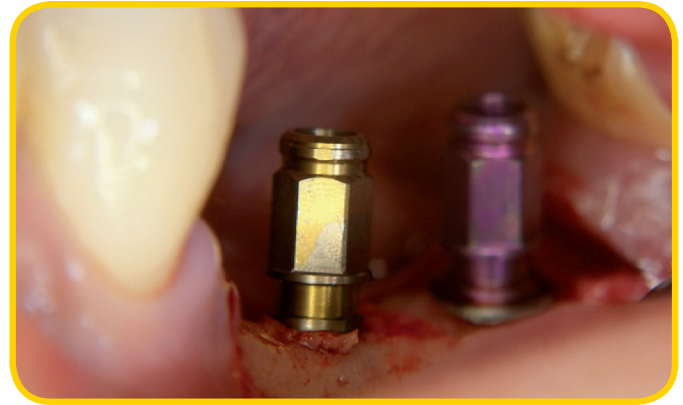

# Surgical user report with eight IMPLA Cylindrical implants by Dr. Philipp Plugmann MSc MBA, Leverkusen

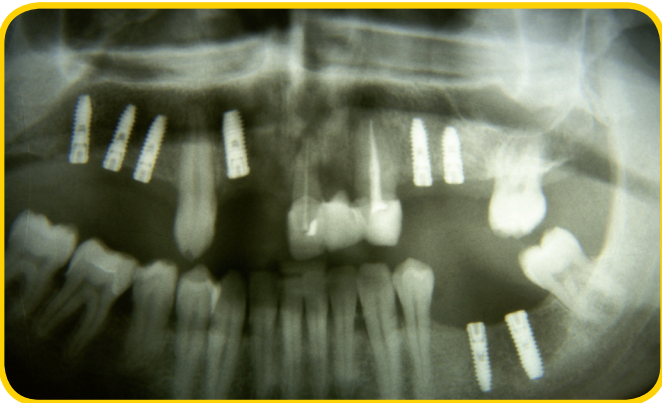
While treating the lower jaw, I came across a D1 bone. Once again, I chose to use the IMPLA Cylindrical implant, only this time for its self-tapping properties. This made the screwing in of the implant so much easier in such compact bone.



Implant bed, positions 35 and 36



Implants with insertion posts, positions 35 and 36



Post-surgical panorama x-ray

The final treatment with dentures is to follow in the autumn of this year. You will hear more about this in the next IMPLA newsletter.

This patient was treated by:

Dr. med. dent. Philipp Plugmann, MSc MBA  
Doctor of Dental Medicine (DMD)  
Ludwig-Erhard-Platz 1  
51373 Leverkusen  
Germany

Quality management certified practice according to ISO 9001:2008. Supervision practice of the German Society for Oral Implantology, Deutschen Gesellschaft für orale Implantologie (DGOI) Area of expertise: BDIZ Implantology Certified since 2007, re-certified until 2017



Would you like to report your cases to us? Then simply get in touch:

Telephone  
+49 6003 814-365  
or  
e-mail  
[export@schuetz-dental.de](mailto:export@schuetz-dental.de)

We look forward to hearing from you!

**Please note: This report is not a user-manual. Please take strict note of the instructions for this system. The responsibility lies with the user.**